

DDX Retinal Detachments vs. Vitreous Membranes *Automatic Diagnoses using Standardized Echography*

Karl C. Ossoinig (University of Iowa, Iowa City, USA)

Evolution of the A₁ Sign:

During the 1960's, the signal processing in diagnostic A-scans, i.e., the way A-scan echograms are being shaped and are displayed, has been optimized and standardized¹. This standardization includes a precise and meaningful recording of the *Reflectivity* of an acoustic surface such as the surface of a retina or that of a vitreous membrane. This reflectivity is expressed by the maximal spike height (obtained from the surface (at *Tissue Sensitivity* of the instrument and with perpendicular sound beam incidence). The reflectivity is indicated by the height of the maximal echo spike as a percentage of the display height.

During the 1970's, clinical experience taught us that retinal surfaces invariably produce 100 % high maximal spikes ("100% reflectivity"), provided their diameters are equal or larger than the diameter of the exploring ultrasound beam, which at *Tissue Sensitivity* is about 3 mm. Most membranous surfaces reflect clearly less than 98% and thus clearly differ from detached retina (Fig. 1).

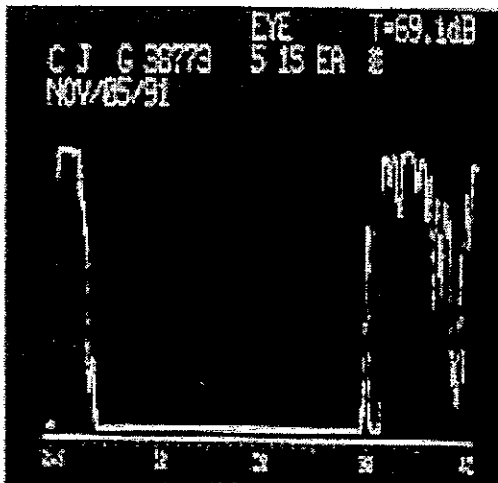


Figure 1A: posterior vitreous membrane represented by 70% high maximal spike in front of the fundus signals.

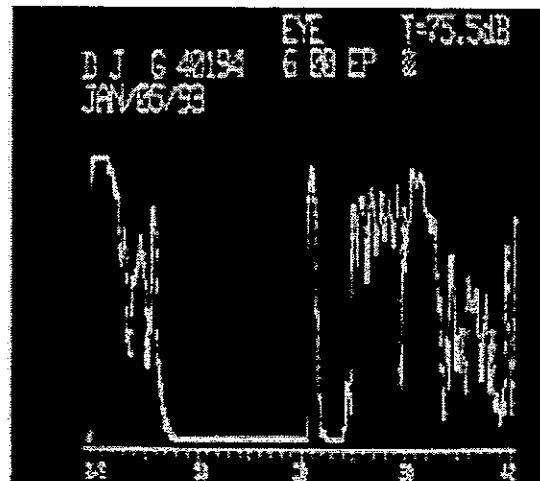


Figure 1B: retinal detachment (represented by 100% high maximal spike) overlying metastatic choroidal carcinoma (group of 85 % high spikes in front of 100% high scleral signal).

Very dense fibro-vascular membranes may not differ from retinal surfaces regarding their reflectivity. However, we also noted, that these most dense membranes have a coarse surface in contrast to retinal surfaces which always (even if folded) are smooth. This surface property is another A-scan criterion useful for the differentiation between retinal and membranous surfaces: the A-scan technology optimized during the 1960's also includes the filtering of high-frequency oscillations. This filtering is applied in a measured and standardized fashion so that the high-frequency oscillations are not completely lost but reduced to tiny "high-frequency nodules" distributed along the ascending and descending limbs of an echo spike. Smooth surfaces produce only a minimum number of these nodules along the left (ascending) limbs of their

maximized echo spikes, whereas coarse surfaces produce a great number of these. Fig. 2 illustrates this difference in the maximized echo spikes obtained from a detached retina (typically less than 3 nodules) and a dense vitreous membrane (characteristically more than 4 nodules).

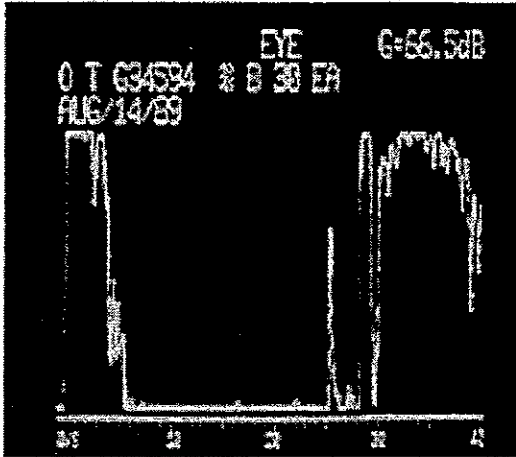


Figure 2A: retinal detachment (100 % high maximal spike in front of fundus signals) behind a posterior vitreous membrane (60% high spike). The retinal spike is 100% high indicating specifically high reflectivity of retinal surface. The left ascending limb of the retinal spike shows only 2 high-frequency nodules indicating the smooth surface of the retina.

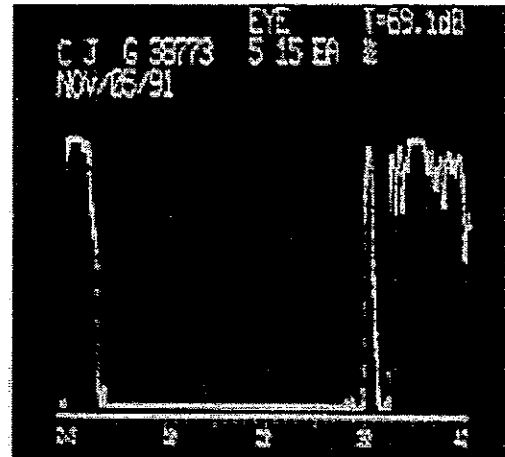


Figure 2B: very dense posterior vitreous membrane represented by 100% high spike revealing its very high reflectivity. The left ascending limb of this maximal membrane spike is loaded with high-frequency nodules indicating the coarse surface of this membrane.

With these findings a powerful diagnostic differential criterion was borne: the **A₁ Sign**: When the maximized surface spike is 100% high (specifically high reflectivity) and has fewer than 3 high frequency nodules along its left ascending limb (smooth surface), retinal detachment is diagnosed. When on the other hand, the maximized spike is less than 98% high, a membrane is diagnosed regardless of the number of high-frequency nodules found along its left ascending limb (weak reflectivity with smooth or coarse surface). When, however, a 100% high maximal spike is combined with more than 3 high-frequency nodules distributed along its left ascending limb, a dense fibro-vascular membrane is diagnosed.

Value of the A₁ Sign:

During 1987 / 88 a prospective clinical study was undertaken ² to test the validity of 8 A-scan and B-scan criteria (including the A₁ Sign) in the diagnosis of retinal detachment in eyes with severe diabetic vitreo-retinopathy or severe trauma. Standardized Echography attempting to utilize all of these 8 criteria was performed prior to vitrectomy or enucleation. The A₁ Sign was clearly the best of all 8 differential criteria (100% availability, 100% specificity, 98% sensitivity).

There were a few drawbacks to the great value of the A₁ Sign, however: the examiner had to maximize the echo signal from the surface in question. Displaying the A₁ Sign can be

time-consuming and requires skills in order to keep the perpendicular approach (maximal signal) long enough on the screen to evaluate both height and left ascending limb (or at least long enough to freeze the echogram and evaluate these items from the frozen echogram). Depending on the skills of the examiner and the cooperation of the patient, the evaluation of an A₁ Sign as described above may take between 2 and 5 minutes.

The Software Solution:

During the past few years, the author developed software together with Quantel Medical that dramatically simplifies and the A₁ Sign and automatically displays the result of the testing on the screen of the instrument. The entire A₁ Sign evaluation may be done in 5 to 10 seconds even by less experienced and skilled examiners and is more objective and accurate than previously.

The software allows the instrument to "remember" the maximal signal obtained from the surface in question during a scanning procedure and evaluates both the height of the resulting maximal signal and the number of the high-frequency nodules encountered along its left ascending limb. It then indicates the result as either "Retina" when the maximal signal is > 98% of the display height and fewer than 3 high-frequency oscillations are encountered between 10 and 95% height of the ascending limb.

The diagnosis is "Retina +++" if no high-frequency oscillation occurs in that stretch of left limb; it is "Retina ++", if one high-frequency nodule occurs and "Retina +", if 2 such nodules appear. The diagnosis is "Membrane", if the spike height is >98% but > 3 high-frequency nodules are detected along the left ascending limb of the maximized spike. It reads "Membrane +++", if > 5 high-frequency nodules are detected; it is "Membrane ++", if 5 are noted, and "Membrane +" if 4 high-frequency nodules exist along the left ascending limb. The result is termed "equivocal", if 3 high-frequency nodules are present. Similarly a membrane is diagnosed and qualified as +++, ++ or +, if the maximal height is between 75 and 98% of the display height in dependence on how many high-frequency nodules are present. The maximal spike height in % of the display height and the number of high-frequency oscillations are listed in parenthesis next to the diagnosis to give the examiner a clue why the instrument chose the make a stronger diagnosis (+++ to ++) or a weaker one(+) or no diagnosis ("equivalent"). Figure 3 presents clinical examples.

The software explained not only supports the diagnosis of retinal detachment, but makes it more objective and reliable; it , in particular, makes the differential diagnosis between retinal detachments and dense fibro-vascular membranes much easier and quicker.

Once the instrument indicates retinal detachment (particularly when the diagnosis is marked as +++ or ++), no further effort on the part of the examiner is needed. The examiner has to make sure, however, that other strongly reflective and smooth surfaces such as a glass foreign body or an air bubble are not present within the vitreous cavity (the software program would not be able to differentiate between these surfaces and a detached retina.

If, on the other hand, a membrane is diagnosed by the software, the examiner may have given the instrument the wrong input by not aiming a perpendicular beam at the surface in question during the scanning procedure. In this situation It is advisable to go back to scanning and to try harder to display a maximal surface spike. Only if repeated attempts to come up with a retinal detachment diagnosis fail, the diagnosis of membrane carries a great accuracy too.

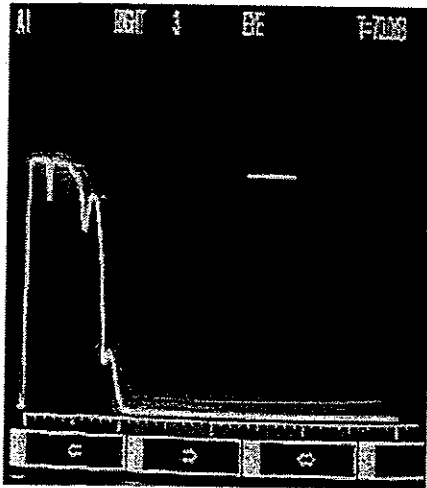


Figure 3A: Once the A₁ program is chosen from the menu, the instrument sensitivity is automatically set at Tissue Sensitivity (T) and a gate appears on the display (width and location may be changed to adjust for the location of the echo spike under scrutiny).

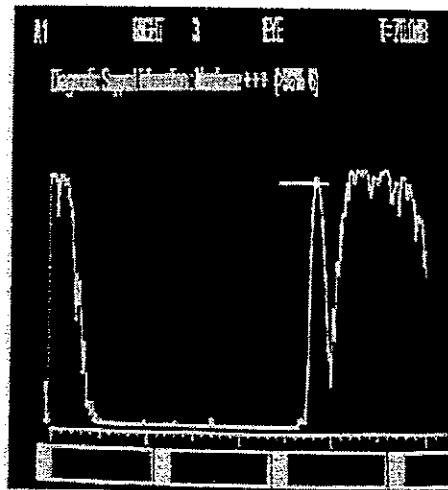


Figure 3B: this is the maximal surface signal obtained by the examiner during a scanning (while the foot switch was depressed). As soon as the foot switch was released, the instrument evaluated the maximal spike and displayed the result: "Membrane +++ (>98% 6)".

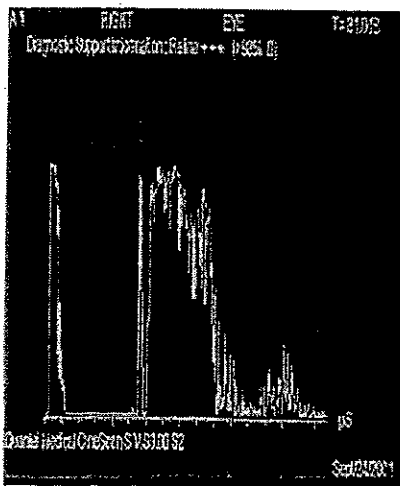


Figure 3C: the resulting diagnosis was: "Retina +++ (>98% 0)", i.e., the surface in question was high-reflective (>98% maximal spike height) and extremely smooth (0 high-frequency nodules) thus strongly indicating RD.

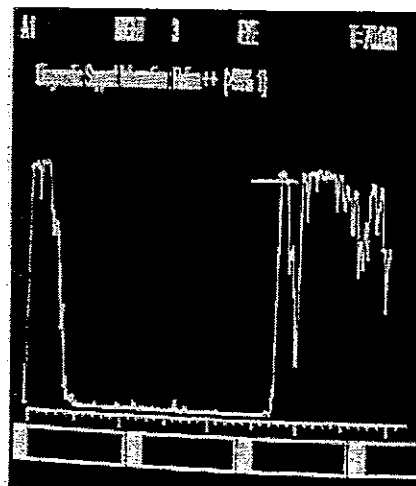


Figure 3D: the resulting diagnosis was "Retina ++ (>98% 1)". Because of the slightly lessened smoothness of the surface in question the diagnosis is not quite as strong as in Figure 3C, but still clearly RD.

Bibliography:

- 1) KC Ossoinig: Standardized Echography – Basic Principles, Clinical Applications, and Results. In: *Int. Ophthalmol. Clin.* Boston: Little Brown and Co., 1979; 19(4):127-210.
- 2) KC Ossoinig: Detached Retina vs. Dense Fibro-vascular Membrane: A-scan and B-scan signs for the differential diagnosis with Standardized Echography. In: *Ultrasonography in Ophthalmology 15* (proceedings of the 15th SIDUO ongress, Cortina, Italy 1994 (G.Cennamo and N.Rosa, eds., Kluwer Academic Publishers/Dordrecht/Boston/London 1997.